

ORIGINAL ARTICLE

Comparison of Haglund Height and Angle in Persons with or without Insertional Achilles Tendinopathy

Praphulla Shrestha¹, Pralhad Kumar Chalise¹, Anil Kumar Mishra¹¹ Nepal Medical College Teaching Hospital, Gokarneshwore, Kathmandu, Nepal.

ABSTRACT

BACKGROUND

Insertional Achilles tendinopathy (IAT) has been associated with Haglund deformity of the posterosuperior calcaneal tubercle. During surgical treatment of IAT, excision of the Haglund deformity is being performed as a routine, which adds morbidity. We wanted to find out if it is that really necessary or not by comparing the Haglund height and angle between patients with IAT and the control group in our population.

METHODS

A cross-sectional study was performed on 68 patients in the department of Orthopaedics and Trauma from November 2023 to April 2024 after ethical approval (Ref no. 27-080/081). Measurement of Haglund height and angle was performed in the hospital PACS system. Other relevant angles and lines were also measured. Other important X-ray findings were also noted.

RESULTS

The mean Haglund height and Haglund angle in the IAT group were 3.97 ± 1.65 mm and $7.35 \pm 3.15^\circ$ respectively. In the control group, the mean Haglund height and Haglund angle were 2.99 ± 1.33 mm and $5.38 \pm 2.49^\circ$ respectively. Both Haglund height and angle were statistically significant when compared between groups. Also, the presence of posterior heel spur, calcification over the tendoachilles, and sclerosis of the posterior calcaneal tuberosity in x-ray was statistically significant in comparison between the two groups.

CONCLUSION

Our study concludes that Haglund deformity has a role in the pathogenesis of IAT, and its excision might be justified. The presence of posterior heel spur, calcification over the tendoachilles, and sclerosis of the posterior calcaneal tuberosity are key features in the x-ray of IAT.

KEYWORDS

Insertional Achilles Tendinopathy, Haglund Deformity, Haglund Height, Haglund angle

INTRODUCTION

The irritation of the Achilles tendon by the posterosuperior edge of the calcaneus also commonly known as the Haglund deformity¹ is a common cause of Insertional Achilles tendinopathy (IAT).² The diagnosis of IAT is made by the presence of tenderness over the Haglund tuberosity and/or presence of posterior calcaneal spur in x-ray.³ Radiologically, the Haglund tubercle's height and angle have been measured by bump height & bump calcaneal ratio, X/Y ratio, BRINK angle, Haglund height & Haglund angle

measurement, etc. Other classical radiographic measurements are Fowler-Phithe lip angle, Chauveaux-Liet angle, Henegan-Pavlov Parallel pitch lines and calcaneal pitch angle.^{4, 5} Surgical removal of the Haglund deformity has been performed as a part of the treatment of IAT.⁸ In this study, we want to find if the removal of the Haglund deformity is justified or not in Nepali population by comparing the measurement of Haglund angle and height in patients with or without IAT.

METHODS

After ethical approval from the Institutional Review Committee (Ref no. 27-080/081), all patients with Insertional Achilles Tendinopathy (IAT) presented to the outpatient department of Orthopedics from November 2023 to April 2024 were enrolled in the study after obtaining informed written consent. It was a cross-sectional study. All skeletally mature patients of both sexes with

CORRESPONDENCE

Dr Praphulla Shrestha

Department of Orthopedics, Nepal Medical College Teaching Hospital, Gokarneshwore-7, Kathmandu

Tel: +977-9851156488, Email: praphs@gmail.com

IAT were taken into the study. The total number of patients was 34 in each group - patients with IAT group and control group.

The patients with non-insertional Achilles tendinopathy, with previous history of Achilles tendon injury or surgery of the tendon,

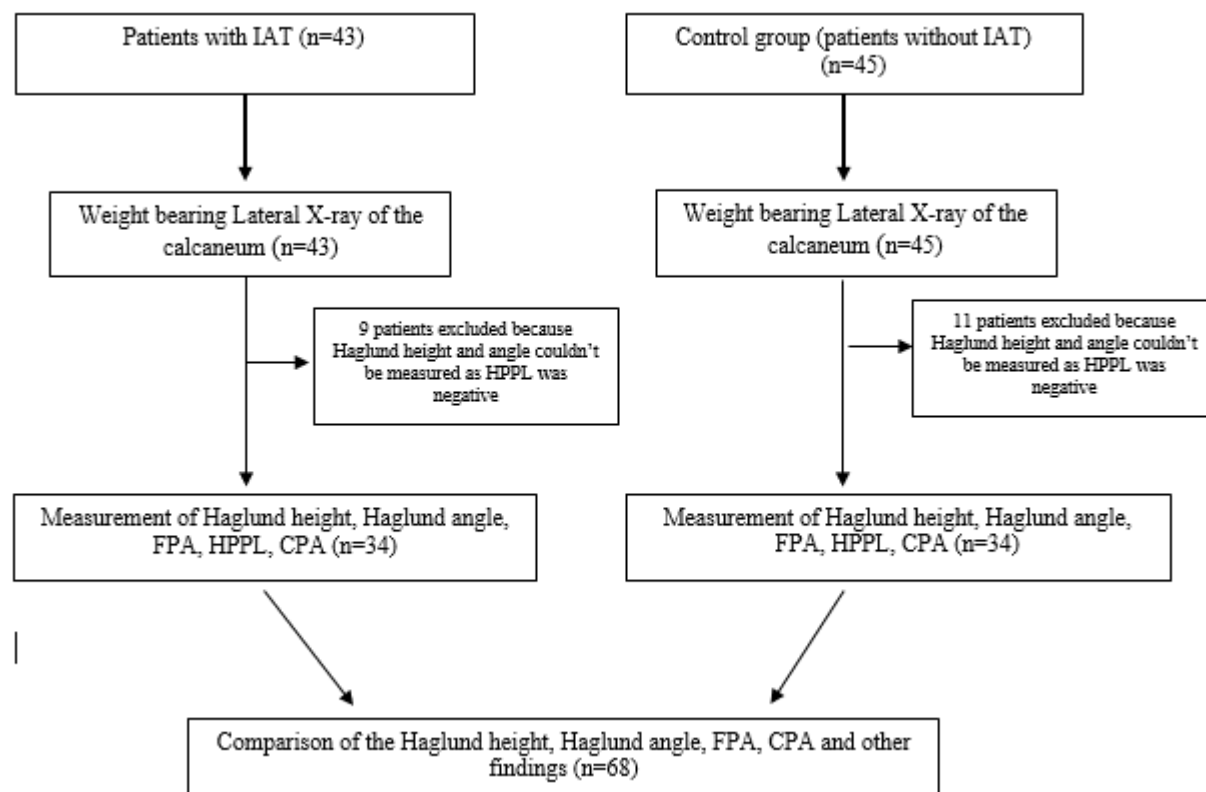


Fig. 1: Flowchart showing patient selection.(n: number of patients, IAT: Insertional Achilles Tendinopathy, FPA: Fowler-Philip Angle, HPPL: Henegan-Pavlov Parallel Pitch Lines, CPA: Calcaneal Pitch Angle)

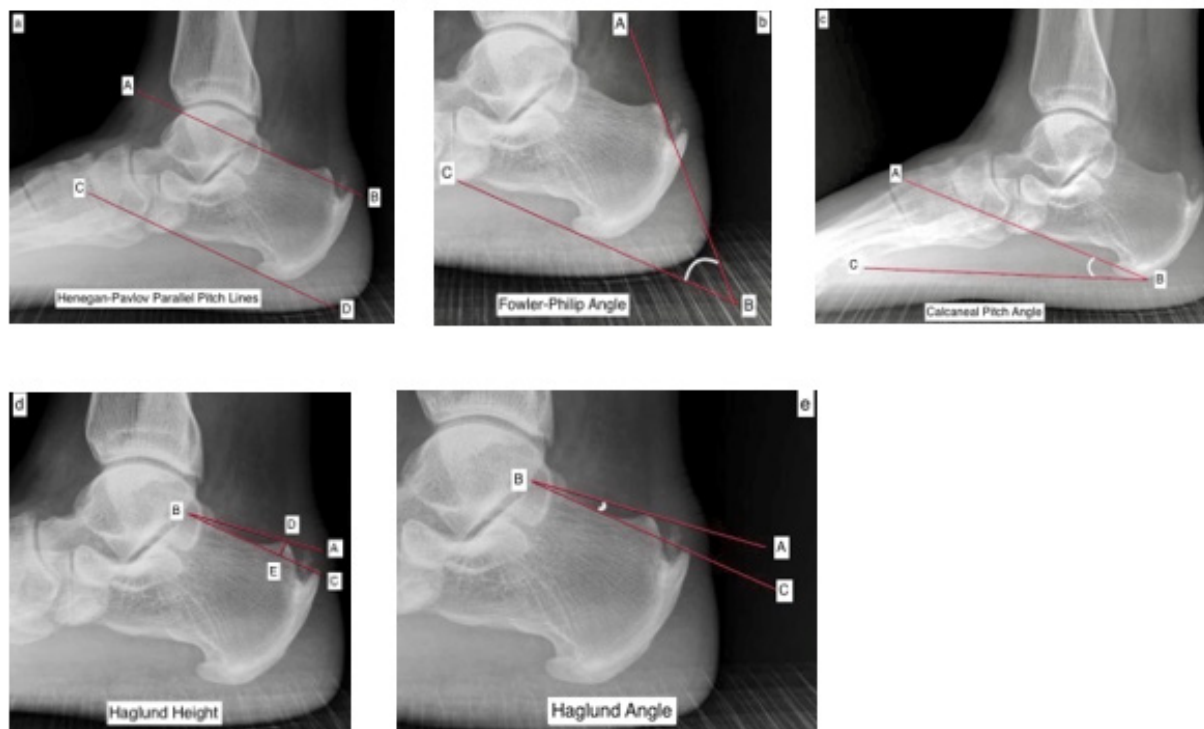


Fig. 2: Illustration showing measurement of different lines and angles a. Henegan-Pavlov Parallel Pitch Lines b. Fowler Philip Angle c. Haglund Height and d. Haglund Angle

were excluded from the study. For the control group, the patients with other affections unrelated to the Achilles tendon, without any bony deformity related to the foot and ankle and who had been investigated with the lateral weight bearing radiographs of the ankle for other purposes were enrolled into the control group. The patients with a previous history of Achilles tendon injury or surgery of Achilles tendon were excluded from the study in the control group. Demographic and other required data were entered in the proforma. Clinical examination was done, and findings were noted.

The lateral radiographs of the ankle of the patients were obtained, and findings were noted. The PACS hospital system database was used for radiographic assessment & measurements, and data were recorded from both groups. The patients and the radiographs of both the groups were assessed by a single examiner who is a senior faculty in the Orthopedics department.

The radiological parameters like Haglund height and angle, as mentioned by Lee et al,⁷ Fowler Philip angle, Henegan-Pavlov Parallel lines and calcaneal pitch angle were measured, and significant findings like posterior and plantar calcaneal spur, tendoachilles calcification, sclerosis of the posterior calcaneal tuberosity, os trigonum etc. were noted. Total number of patients in the IAT group was 43 but 9 patients were excluded from the study because it was unable to measure Haglund height and angle as mentioned by Lee et. al.⁷ in these patients because the Henegan-Pavlov Parallel Pitch Lines were negative i.e. the superior parallel line did not touch or cross the Haglund tubercle. We included 45 consecutive patients in control group as 11 patients in the group had to be excluded from the group because we were unable to measure Haglund height and angle as mentioned by Lee et. al. in these patients as the Henegan-Pavlov Parallel Pitch Lines were negative i.e. the superior parallel line did not touch or cross the Haglund tubercle. The final control group was made of 34 patients to compare in a 1:1 ratio with the patients in the group with IAT. The data were entered in SPSS 16. The data was processed, and results were obtained. Descriptive statistics was presented in the form of frequency, percentage, mean, and standard deviation. The level of significance was set at p value < 0.05. [Fig. 1 and 2].

RESULTS

The mean age of the patients in IAT group is 52.53 ± 11.97 while in control group was 50.50 ± 11.17 ($p=.472$). The age of the patients ranged from 27 to 76 years in the IAT group and control group ranged from 31 to 70 years. In the IAT group, there were 13 (38.2%) males & 21 (61.8%) females, and in the control group, there were 15 (44.1%) males and 19 (55.9%) females ($p=.622$). Body mass index (BMI) in IAT group was 12 (35.3%), 16 (47.1%) and 6 (17.6%) in normal, overweight and obese patients respectively. In the control group, the body mass index (BMI) was 17 (50%), 11 (32.4%), and 6 (17.6%) in normal, overweight, and obese patients, respectively. The mean BMI of the patients in the IAT group was 27.28 ± 4.34 , with a range from 22.20 to 44.58. Similarly, in the control group, the mean BMI was 26.34 ± 3.71 and ranged from 20.22 to 33.51. In IAT group 64.7 % patients were overweight or obese while only 50% patient were overweight or obese in patients of control group ($p=.344$).

Side of involvement was right in 19 (55.9%) and left in 15 (44.9%) patients in IAT group while right in 14 (41.8%) and left in 20 (58.2%) patients in control group. The control group was advertently matched with the IAT group as much as possible in terms of age and gender (Table 1). [Fig. 3].

Table 1. Age, gender, and BMI characteristics of IAT and control group

Variable	IAT group (n=34)	Control group (n=34)	p value
Age	52.53 ± 11.97	50.50 ± 11.17	.472
Sex (Females)	61.8%	55.9%	.622
BMI	27.28 ± 4.34	26.34 ± 3.71	.344

BMI: Body Mass Index, IAT: Insertional Achilles Tendinopathy

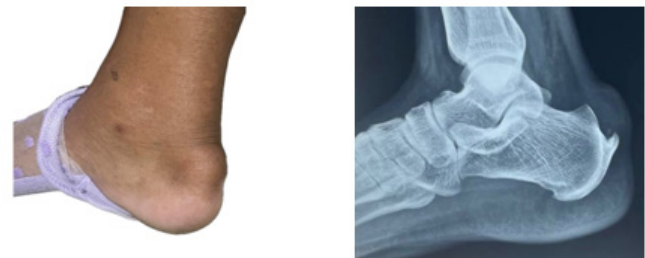

Fig. 3: Clinical (left) and X-ray (right) picture of Insertional Achilles Tendinopathy with Haglund deformity

The average Haglund height, Haglund angle, Fowler-Philip Angle, and the calcaneal pitch angle in the IAT group and control group were calculated and compared between both groups. Haglund height ($p=.009$) and angle ($p=.006$) were found to be statistically significant while Fowler-Philip ($p=.294$) and calcaneal pitch angles ($p=.121$) were found to be insignificant between the two groups (See Table 2). Among patients with IAT, on x-rays, posterior calcaneal spur was present in 31 out of 34 patients (91.17%), sclerosis over posterior calcaneal tuberosity was present in 21 out of 34 patients (61.76%), calcification over tendoachilles was present in 8 out of 34 (23.5%) and os trigonum was present in 2 out of 34 (5.88%) patients. Three patients (8.82%) in the IAT group who were clinically diagnosed as IAT had no posterior heel spur. Plantar heel spur was present in 22 out of 34 (64.7%), and in the control group, it was present in 14 out of 34 (58.8%). This plantar heel spur was present in the control group because we had included patients with plantar fasciitis in this group.

DISCUSSION

This study was aimed at measuring different radiographic parameters in patients with insertional Achilles tendinopathy (IAT) and their significance, especially the measurement of Haglund height and angle measurement in x-rays. By measuring the Haglund height and angle, we wanted to find out whether the Haglund tubercle is the culprit or not for the causation of

Table 2: Comparison of different angles between the group with IAT and the control.

Variable	Group	Mean \pm S.D.	p value
Haglund Height (HH)	Patients with IAT	3.97 \pm 1.65 mm	0.009
	Control	2.99 \pm 1.33 mm	
Haglund Angle (HA)	Patients with IAT	7.35 \pm 3.15°	0.006
	Control	5.38 \pm 2.49°	
Fowler-Philip Angle (FPA)	Patients with IAT	60.66 \pm 5.53°	0.294
	Control	59.12 \pm 6.21°	
Calcaneal Pitch Angle (CPA)	Patients with IAT	25.15 \pm 4.80°	0.121
	Control	23.42 \pm 4.29°	

IAT: Insertional Achilles Tendinopathy

IAT and justification for the surgical removal of the Haglund tubercle, which added an extra procedure and morbidity to the patient. So, on this background, different parameters have been measured, and the null hypothesis has been accepted.

The average age in the IAT group is 52.53 \pm 11.97, which is comparable to the other published literature as in their paper the average age was 50-58 years.^{7, 9} This shows that IAT is common in the age group 40 and above. In the IAT group, 85% of the patients were more than 40 years of age. So, our literature aligns with the global published literature. The female gender was common in our study, which has also been shown in other published literature.^{3, 7} The age and sex were advertently matched in the control group according to the IAT group.

BMI was inadvertently matched in both the IAT and control groups. It was an added advantage in matching the groups. The association of BMI with IAT cannot be established in this study, although more patients with IAT were overweight or obese (64.7%) than in the control group (50%). The valid reason here might be because we had included patients with other types of heel, foot or ankle pain especially patients with plantar fasciitis and ankle sprain in the control group and those patients are also likely to have high BMI.^{10, 11} In the studies by Lee W et al⁷ and Wezenbeek et al¹² high BMI has been associated to IAT.

The radiographic measurements that were measured in our study were Haglund Height, Haglund Angle, Fowler-Philip angle, Henegan-Pavlov Parallel Pitch lines, and Calcaneal pitch angle. The difference between the Haglund height and angle in the IAT and control group was found to be significant statistically. The Haglund deformity and its role in the etiology of Insertional Achilles Tendinopathy is indicated by this finding. It also means that the shape of the posterior and posterosuperior part of the calcaneus may play an important role in the pathogenesis of Insertional Achilles Tendinopathy. This is a very important finding which has also been shown in other published literatures.¹³ Different authors have recommended the excision of the Haglund tubercle as a part of open or endoscopic surgery for the Insertional Achilles Tendinopathy (IAT) and they have reported good functional results in their study.¹⁵ So, our study has highlighted the role of Haglund deformity as a part of the pathogenesis of IAT in the

Nepali population, and its excision is justified as it is the culprit in our Nepali patient population also.

Fowler-Philip angle (FPA) and Calcaneal pitch angle has been classically measured in lateral view radiographs to determine the cause for Insertional Achilles Tendinopathy that may lie in the shape and flatness of the posterior calcaneus.^{2, 5} Although there is difference in the Fowler-Phillip angle between the two groups, as shown by other studies also^{2, 14} but there is no statistical significance. As originally described by Fowler and Philip, their angle was >75 degrees in patients with posterior heel pain and was 44-69 degrees in normal individuals.¹⁷ But our study does not show the similar results as mentioned by Fowler and Philip. Other studies have also questioned the significance of this angle in determining its role in association with the etiology of Insertional Achilles Tendinopathy.^{13, 14} Calcaneal pitch is an angle which determines the angle of the lower border of calcaneus with the ground which defines its flatness. This angle is also not significant in our study. This has also been shown in other studies. So, in accordance with other studies, our findings are aligned. Positive Henegan-Pavlov Parallel Pitch lines was a criterion to measure the Haglund Height and Haglund Angle, so it was not amenable for analysis. Although in IAT group, 9 out of 43 patients (20.93%) had negative Henegan-Pavlov Parallel Pitch line and had to be excluded from the study group in comparison to the control group in which 11 out of 45 patients (24.44%) had negative Henegan-Pavlov Parallel Pitch line and had to be excluded from the control group.

Posterior calcaneal spur, sclerosis over calcaneal tuberosity, and calcification over tendoachilles in radiographic findings were significant as compared to control in our study. These findings are consistent with different published literature.^{2, 7, 13} So, the presence of posterior calcaneal spur, sclerosis over the posterior calcaneal tuberosity and calcification over the tendoachilles can be mentioned as a feature of IAT.

As it was a cross-sectional study, we cannot validate the role of surgical excision of the Haglund tubercle, for which a randomized clinical trial is needed. In this study, bilateral cases were excluded, and although there were only four cases, this prohibited us from knowing the behavior of bilateral cases. The sample size was small, so the findings cannot be generalized, and we need further study in a large population to validate these findings. Observer bias might

be an issue as all X-rays were examined by the primary author only.

CONCLUSION

This study has provided evidence of Haglund deformity's role in the pathogenesis of Insertional Achilles Tendinopathy in the Nepali population. So, the surgical removal of Haglund deformity as a part of treatment of Insertional Achilles Tendinopathy is justifiable in our population. It also has endorsed the use of weight-bearing lateral view x-ray of the calcaneus to see the features of IAT. The x-ray findings like posterior calcaneal spur, sclerosis over the posterior calcaneal tuberosity, and calcification over the tendoachilles can be an important finding to diagnose IAT.

ACKNOWLEDGEMENT

We would like to thank Dr. Bashudev Poudel, Dr. Milan Shrestha, and Dr Rajesh Kushwaha for their help in data accumulation and Dr Nischal Dhakal for his help in statistics.

REFERENCES

1. Syed TA, Perera A. A Proposed Staging Classification for Minimally Invasive Management of Haglund's Syndrome with Percutaneous and Endoscopic Surgery. *Foot Ankle Clin.* 2016 Sep;21(3):641-64. <https://doi.org/10.1016/j.fcl.2016.04.004>
2. Nakajima K. Insertional Achilles tendinopathy: A radiographic cross-sectional comparison between symptomatic and asymptomatic heel of 71 patients. *Eur J Radiol Open.* 2024 Jun;12:100568. <https://doi.org/10.1016/j.ejro.2024.100568>
3. Kang S, Thordarson DB, Charlton TP. Insertional Achilles Tendinitis and Haglund's Deformity. *Foot Ankle Int.* 2012 Jun;33(6):487-91. <https://doi.org/10.3113/FAI.2012.0487>
4. Tang SC, Tu KC, Liao WJ, Hsu CT, Shih HT, Tung KK, et al. Novel Radiographic Measurements for Operatively Treated Haglund's Deformity. *Tomography.* 2022 Feb 1;8(1):284-92. <https://doi.org/10.3390/tomography8010023>
5. Tourné Y, Baray AL, Barthélémy R, Moroney P. Contribution of a new radiologic calcaneal measurement to the treatment decision tree in Haglund syndrome. *Orthop Traumatol Surg Res.* 2018 Dec;104(8):1215-9. <https://doi.org/10.1016/j.otsr.2018.08.014>
6. Nischal N, Chandra Lalita K, Iyengar KP, Reilly I, Botchu R. Angle of BRINK - a new way to measure Haglund's deformity. *Skeletal Radiol.* 2023 Feb;52(2):193-8. <https://doi.org/10.1007/s00256-022-04169-4>
7. Lee W, Giro ME, Crymes C. Association of Haglund Deformity Size and Insertional Achilles Tendinopathy. *Foot Ankle Int.* 2023 Aug;44(8):719-26. <https://doi.org/10.1177/10711007231168625>
8. Irwin TA. Current Concepts Review: Insertional Achilles Tendinopathy. *Foot Ankle Int.* 2010 Oct;31(10):933-9. <https://doi.org/10.3113/FAI.2010.0933>
9. Chen W, Cloosterman KLA, Bierma-Zeinstra SMA, Van Middelkoop M, De Vos RJ. Epidemiology of insertional and midportion Achilles tendinopathy in runners: A prospective cohort study. *J Sport Health Sci.* 2024 Mar;13(2):256-63. <https://doi.org/10.1016/j.jshs.2023.03.007>
10. Riddle DL, Pulisic M, Pidcoke P, Johnson RE. RISK FACTORS FOR PLANTAR FASCIITIS: A MATCHED CASE CONTROL STUDY. *J Bone Jt Surg-Am Vol.* 2003 May;85(5):872-7. <https://doi.org/10.2106/00004623-200305000-00015>
11. Vuurberg G, Altink N, Rajai M, Blankevoort L, Kerkhoffs GMMJ. Weight, BMI and stability are risk factors associated with lateral ankle sprains and chronic ankle instability: a meta-analysis. *J ISAKOS Jt Disord Orthop Sports Med.* 2019 Nov;4(6):313-27. <https://doi.org/10.1136/jisakos-2019-000305>
12. Wezenbeek E, Willems T, Mahieu N, De Muynck M, Vanden Bossche L, Steyaert A, et al. The Role of the Vascular and Structural Response to Activity in the Development of Achilles Tendinopathy: A Prospective Study. *Am J Sports Med.* 2018 Mar;46(4):947-54. <https://doi.org/10.1177/0363546517750854>
13. Lu CC, Cheng YM, Fu YC, Tien YC, Chen SK, Huang PJ. Angle Analysis of Haglund Syndrome and its Relationship with Osseous Variations and Achilles Tendon Calcification. *Foot Ankle Int.* 2007 Feb;28(2):181-5. <https://doi.org/10.3113/FAI.2007.0181>
14. Sundararajan PP, Wilde TS. Radiographic, Clinical, and Magnetic Resonance Imaging Analysis of Insertional Achilles Tendinopathy. *J Foot Ankle Surg.* 2014 Mar;53(2):147-51. <https://doi.org/10.1053/j.jfas.2013.12.009>
15. Jerosch J. Endoscopic Calcaneoplasty. *Foot Ankle Clin.* 2015 Mar;20(1):149-65. <https://doi.org/10.1016/j.fcl.2014.10.004>
16. Pi Y, Hu Y, Guo Q, Jiang D, Xie X, Zhao F, et al. Calcaneoplasty coupled with an insertional Achilles tendon reattachment procedure for the prevention of secondary calcaneal impingement: a retrospective study. *Ther Adv Chronic Dis.* 2020 Jan;11:2040622320944793. <https://doi.org/10.1177/2040622320944793>
17. Solan M, Davies M. Management of Insertional Tendinopathy of the Achilles Tendon. *Foot Ankle Clin.* 2007 Dec;12(4):597-615. <https://doi.org/10.1016/j.fcl.2007.07.005>